



# SPLINTING TECHNIQUES

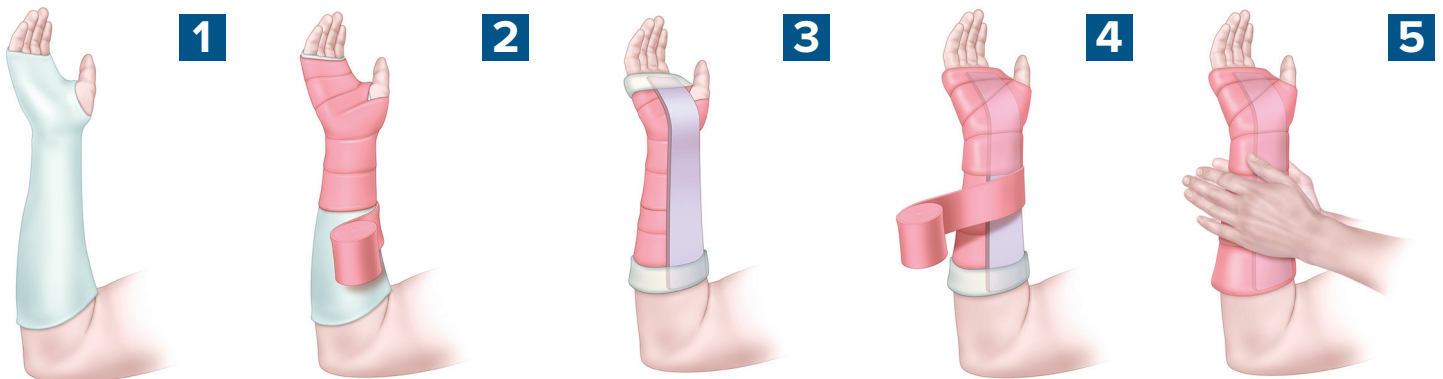
## BASELINE MATERIALS

- Stockinette
- Splinting material
- Plaster
  - Upper extremity: 8–10 layers
  - Lower extremity: 10–12 layers
- Fiberglass
- Padding
- Elastic bandaging
- Bucket/receptacle of water (the warmer the water, the faster the splint sets)
- Trauma shears

## BASELINE PROCEDURE

Measure and prepare the splinting material.

- Length: Measure out the dry splint on the contralateral extremity
- Width: Slightly greater than the diameter of the limb



**1**  
Apply the stockinette to extend 2" beyond the splinting material.

**2**  
Apply 2–3 layers of padding over the area to be splinted and between digits being splinted. Add an extra 2–3 layers over bony prominences.

**3**  
Lightly moisten the splinting material. Place it and fold the ends of stockinette over the splinting material.

**4**  
Apply the elastic bandaging.

**5**  
While still wet, use palms to mold the splint to the desired shape.

**6**  
Once hardened, check neurovascular status and motor function.

# POSTERIOR LONG ARM SPLINT



## INDICATIONS

- Olecranon fractures
- Humerus fractures
- Radial head and neck fractures

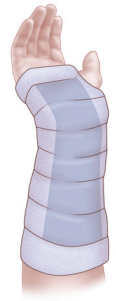## CONSTRUCTION

- Start at posterior proximal arm
- Down the ulnar forearm
- End at the metacarpophalangeal joints

## APPLICATION

- Cut hole in stockinette for thumb
- Elbow at 90°
- Forearm neutral position with thumb up
- Neutral or slightly extended wrist (10–20°)

# VOLAR SPLINT



## INDICATIONS

- Soft tissue injuries of the hand and wrist
- Carpal bone fractures
- 2nd–5th metacarpal base fractures

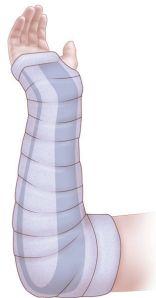
## CONSTRUCTION

- Start at palm at the metacarpal heads
- Down the volar forearm
- End at distal forearm

## APPLICATION

- Cut hole in stockinette for thumb
- Forearm in neutral position with thumb up
- Wrist slightly extended (10–20°)
- Like holding a can

# SUGAR TONG SPLINT



## INDICATIONS

- Distal radius and ulna fractures

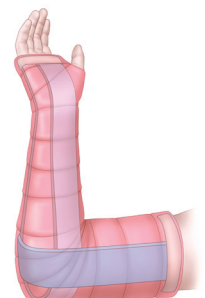
## CONSTRUCTION

- Metacarpal heads on the dorsal hand
- Around elbow
- End at volar metacarpal phalangeal joints

## APPLICATION

- Cut hole in stockinette for thumb
- Elbow at 90°
- Forearm neutral with thumb up
- Slightly extended wrist (10–20°)

# DOUBLE SUGAR TONG SPLINT



## INDICATIONS

- Complex and unstable forearm and elbow fractures

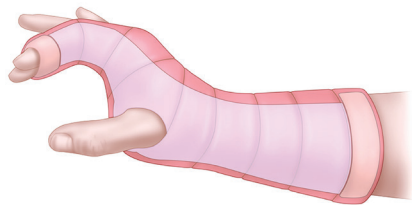
## CONSTRUCTION

- Forearm splint: as above
- Arm splint
  - Start at anterior proximal humerus
  - Around elbow
- End at posterior proximal humerus

## APPLICATION

- Cut hole in stockinette for thumb
- Elbow at 90°
- Forearm neutral with thumb up
- Slightly extended wrist (10–20°)

# RADIAL GUTTER SPLINT



## INDICATIONS

- Fractures and soft tissue injuries of index and 3rd digits
- Fractures of the neck, shaft and base of the 2nd and 3rd metacarpals

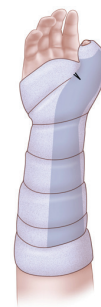## CONSTRUCTION

- Starts at mid-forearm
- Down the radial forearm
- End mid-distal phalanx of 2nd and 3rd digits

## APPLICATION

- Cut hole in stockinette and splinting material for the thumb
- Hand in position of function
- Forearm in neutral position
- Wrist slightly extended
- MCP 50° of flexion
- Proximal interphalangeal and distal interphalangeal joints 5°–10° flexion

# THUMB SPICA SPLINT



## INDICATIONS

- Injuries to scaphoid, lunate, thumb and 1st metacarpal
- Gamekeeper's/Skier's thumb
- De Quervain tenosynovitis

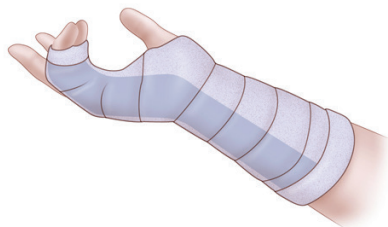
## CONSTRUCTION

- Start at mid-distal phalanx of thumb
- End at mid-forearm

## APPLICATION

- Cut hole in stockinette for thumb
- Cut wedges on both sides of splinting material at MCP joint
- Forearm in neutral position with thumb in wineglass position

# ULNAR GUTTER SPLINT



## INDICATIONS

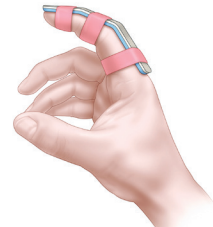
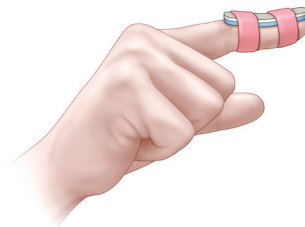
- Fractures and soft tissue injuries of 5th digit
- Fractures of the neck, shaft, and base of 4th and 5th metacarpals

## CONSTRUCTION

- Start at mid-forearm
- Extend down ulnar forearm
- End at mid-distal phalanx
- Include the 4th and 5th digits

## APPLICATION

- Hand in position of function
- Forearm in neutral position
- Wrist slightly extended
- MCP 50° of flexion
- Proximal interphalangeal and distal interphalangeal joints 5–10° flexion
- If boxer's fracture: flex the metacarpal phalangeal joints to 90°



# MALLET FINGER

## INDICATION

- Mallet Finger

## CONSTRUCTION

- Splint only the distal interphalangeal joint

## APPLICATION

- Splint distal interphalangeal joint in hyperextension
- DIP must remain in continuous extension for 6–8 weeks

# FINGER SPLINTS

## INDICATION

- Phalanx fractures
- Tendon repairs

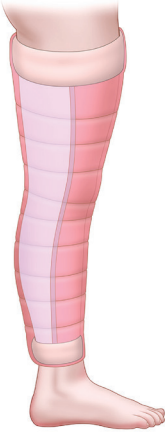## CONSTRUCTION

- Splint across fractured phalanx or repaired tendon

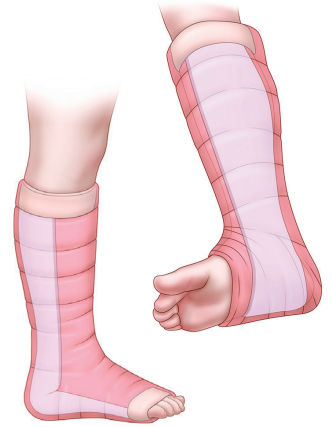## APPLICATION

- If tendon repair: splint in flexion or extension, depending on tendon repaired

# POSTERIOR KNEE SPLINT



# POSTERIOR ANKLE & STIRRUP SPLINTS



## INDICATIONS

- Patients with legs too large for knee immobilizer
- Angulated fractures
- Injuries that require urgent operative fixation

## CONSTRUCTION

- Start just inferior to buttocks crease
- Down the posterior leg
- End approximately 6cm above the malleoli

## APPLICATION

- Slightly flexed knee

## INDICATIONS

- Grade 2–Grade 3 ankle sprains
- Fractures of distal fibula and tibia
- Reduced ankle dislocations
- Can add stirrup splint for unstable ankle fractures

## CONSTRUCTION—POSTERIOR ANKLE

- Start at plantar surface of the metatarsal heads
- Extend up posterior leg
- End at the level of the fibular head

## CONSTRUCTION—STIRRUP

- Laterally, start 3–4cm below the level of fibular head
- Extend under the plantar surface of foot
- End at medial and lateral side of leg to just below fibular head

## APPLICATION

- Place with the patient in the prone position
- Ankle at 90°
- Place posterior ankle splint first

# SPLINTING COMPLICATIONS

- Compartment syndrome
- Ischemia
- Neurologic injury
- Thermal injury
- Pressure sores, skin breakdown
- Infection
- Dermatitis
- Joint stiffness

## RESOURCES

Boyd A, Benjamin H, Asplund C. Principles of Casting and Splinting. *Am Fam Physician*. 2009 Jan 1;79(1):16–22.

### AUTHOR

R. Ian Ross, MD  
Stanford/O'Connor Hospital, Primary Care Sports Medicine Fellow, 2017  
2016–17 Chair, EMRA Sports Medicine Division  
Member, U.S. Figure Skating Sports Science & Medicine

### ILLUSTRATOR

Matthew Holt  
Bodyrender

Eiff MP, Hatch RL. Fracture Management for Primary Care. Philadelphia, PA: Elsevier/Saunders, 2012.

### REVIEWER

Anna L. Waterbrook, MD, FACEP, CAQ-SM  
University of Arizona  
Associate Professor, Dept. of Emergency Medicine  
Associate Program Director, South Campus Residency Program  
Associate Program Director, Sports Medicine Fellowship  
Assistant Team Physician, Intercollegiate Athletics  
2016–18 Chair, ACEP Sports Medicine Section