

Introduction

- Finding blood in the diaper can be the result of a number of different pathologies. Those originating from the GI tract include upper GI bleeds, lower GI bleeds, and hemorrhoids. Potential etiologies stemming from urinary tract include UTI's, trauma to external genitalia, nephrolithiasis, or urolithiasis. Narrowing down these potential diagnoses involves determining whether the blood is originating from the stool or the urine. This case details a particularly infrequent etiology of blood in the diaper.

Case

- A 6-month-old male presents to the ED with blood in his diaper. Two days ago, his mother spotted drops of blood mixed with stool in his diaper. In the following days, blood was found again in diapers filled with solely urine. The pt had a URI a week ago. The pt's symptoms included:
 - Cough
 - Improving rhinorrhea
 - Decreased PO from baseline
- Vitals:
 - RR 48 resp/min
 - O2 sat at 100%
 - HR of 161 BPM**
 - Temp of 38 deg. C (rectal)**
- Physical exam revealed the pt was an alert, nontoxic appearing 6-month-old male who was uncircumcised and had an otherwise unremarkable exam. Child was given Tylenol and a urine analysis was ordered.
- The urinalysis detailed the following:

Table 1: Urinalysis

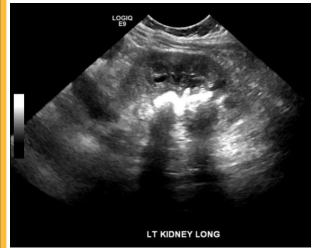
UCOL	UPH	UPRO	UGLU	UKET	UBIL	NITR	EST	URO	UULD	URBC	UWBC	Bacteria
Yellow	7.0	100 mg/dl ABN	Negative	10 mg/dl ABN	Negative	Negative	Large ABN	Normal EU/dl	Large ABN	>182/high power focus	>182/high power focus	NONE

- The table shows elevated red and white blood cells in the urine and an absence of bacteria or nitrates.
- UTI was considered, however, there was no bacteria found in the urine.

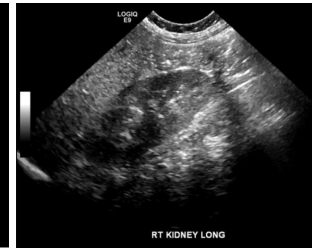Case (continued)

- Following the analysis of the labs, the baby was given ibuprofen for pain management and IV ceftriaxone 435mg/24H for a potential UTI.
- The patient was then followed up with a Renal Bladder Ultrasound (RBUS) that displayed the following images:

Figure 1: L Kidney, Long Axis Figure 2: R Kidney, Long Axis



Ultrasound of the left kidney demonstrates shadowing consistent with a **staghorn calculus** that measured 1.2 x 8 x 1.1 cm. Left kidney length is in normal range at approximately 5.7cm.



Ultrasound of the right kidney is unremarkable with no shadowing or obstructions. Right kidney length is in normal range at approximately the same length as the left kidney.

Hospital Course

- The patient's antibiotic course of ceftriaxone was proven a suitable treatment when a culture came back in the subsequent days revealing the presence of proteus mirabilis.
 - Removal of the calculi occurred at a children's hospital via percutaneous nephrolithotomy 4 weeks later.

Discussion

- Nephrolithiasis normally develops from large dietary intakes of **calcium oxalate** that precipitate in conditions of low urine volume.¹ This etiology accounts for almost all nephrolithiasis cases; however, some stones can develop through precipitating **uric acid** or a combination of uric acid and calcium oxalate stones.^{1,2}
- A diagnosis of nephrolithiasis is usually suspected in an **adult presenting with flank pain, dysuria, and hematuria**, whereas **only 50% of children experience the cardinal symptom of flank pain**.³

Discussion (continued)

- Staghorn calculi** is a subset of nephrolithiasis in which a cast of the kidneys is formed by the stones. Unlike asymptomatic nephrolithiasis which can be treated conservatively through dieting and hydration, this pathology **always requires surgical intervention**.^{3,4}
- In 2004, adult males admitted with nephrolithiasis represented 106 per 100,000 patients in comparison to 64 adult females.⁵ That same year male children with nephrolithiasis made up only 7.8 per 100,000 incoming patients, while female children made up 10.8 per 100,000 incoming patients.⁶ Thus, **male children are the least likely population to develop nephrolithiasis**, and even more rarely, staghorn calculi.
- Diagnosing infants with staghorn calculi can be difficult due to their inability to express the physical symptoms they are experiencing. Blood being found mixed in with stool in a diaper cannot rule out an origin from the urinary tract as it is possible for an infant to urinate blood into a diaper that already has stool in it.
- Parents checking **diapers that solely have urine** could help identify the origin of blood being from the urinary tract as opposed to the GI tract.
- Finding a **high RBC and WBC count** in the urine along with an **absence of bacteria** should direct a clinician to consider nephrolithiasis or other etiologies.
- Confirmation of nephrolithiasis**, or in this case, **staghorn calculi**, is primarily obtained through imaging the pt's renal anatomy using **Renal Bladder Ultrasound (RBUS)** to avoid radiation.^{3,7} **Non-contrast CT** can be used as an alternative imaging modality if an ultrasound proves insufficient. The pathogenesis of our patient may provide insight into future cases of staghorn calculi in infants.^{3,7}

References

- Coe FL. Uric acid and calcium oxalate nephrolithiasis. *Kidney Int.* 1983;24(3):392-403.
- Millman S, Strauss AL, Parks JH, Coe FL. Pathogenesis and clinical course of mixed calcium oxalate and uric acid nephrolithiasis. *Kidney Int.* 1982;22(4):366-70.
- Milliner DS, Murphy ME. Urolithiasis in pediatric patients. *Mayo Clin Proc.* 1993;68(3):241-8.
- Qaseem A, Dallas P, Forciea MA, Starkey M, Denberg TD. Dietary and pharmacologic management to prevent recurrent nephrolithiasis in adults: a clinical practice guideline from the American College of Physicians. *Ann Intern Med.* 2014;161(9):659-67.
- Strope SA, Wolf JS, Hollenbeck BK. Changes in gender distribution of urinary stone disease. *Urology.* 2010;75(3):543-6, 546.e1.
- Roudakova K, Monga M. The evolving epidemiology of stone disease. *Indian J Urol.* 2014;30(1):44-8.
- Parsaud AC, Stevenson MD, Memahon DR, Christopher NC. Pediatric urolithiasis: clinical predictors in the emergency department. *Pediatrics.* 2009;124(3):888-94.