

Introduction

Bowel obstruction caused by blunt abdominal trauma is rare. In this case report, we describe our assessment and management of a 32-year-old man who came to the emergency department (ED) because of bowel obstruction occurring 2 weeks after he sustained blunt abdominal trauma.

Case Report

CC: Nausea and vomiting x 3 days

HPI:

- Three days of NBNB emesis
- Anorexia
- Obstipation x 24 hours
- Seen at same ED 2 weeks prior after an MVA
- Discharged with no indication for imaging
- No PMHx
- No medications
- No allergies

Physical Exam:

- T 97.8 F
- HR 89 beats/min
- BP 126/73 mm Hg
- RR 20 breaths/min
- SpO2 98% on RA
- Rigid and diffusely tender abdomen with involuntary guarding
- Decreased bowel sounds
- Exam otherwise unremarkable

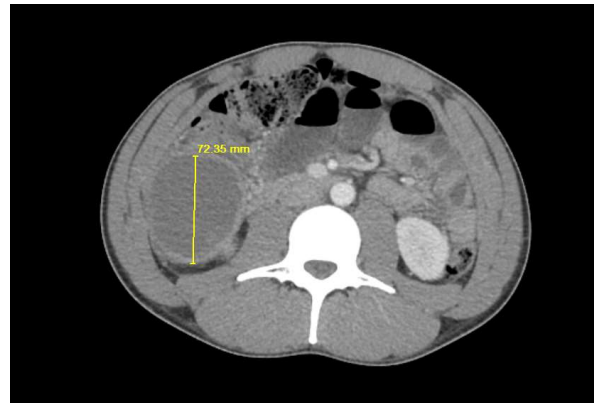


Fig. 1A

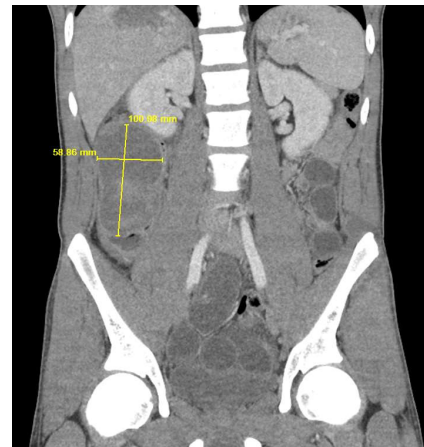


Fig. 1B

Figure 1. CT scan contrast, showing a large (10.1x5.9x7.2 cm) heterogeneous intraluminal 4 collectio with n of fluid in the ascending colon. A. Coronal view. B. Axial view.

What we did

Imaging:

- Contrast CT abd/pelvis
- Bedside US (images not available)

Labs:

- CBC/ BMP/LFTs/Coags
- UA
- Amylase/Lipase
- Type and Screen

Interventions:

- Placement of nasogastric tube
- NPO status

Consults:

- General surgery team

Outcome

- OR on HD #3 for partial colectomy
- Post-op course complicated by wound infection requiring packing on POD #5
- Noted to be doing well at 5 week post-op visit; cleared for all activity

Learning Points

- Blunt abdominal trauma can cause bowel obstruction
- Obstruction can be immediate or delayed in presentation
- Patients presenting with bowel obstruction symptoms and recent history of trauma need imaging
- Preferred imaging modality is CT with IV contrast
- Best management is NPO, NG tube, surgery consult

REFERENCES

1. Isenhour JL, Marx J. Advances in abdominal trauma. *Emerg Med Clin North Am* 2007; 25:713. doi: 10.1016/j.emc.2007.06.002
2. Bodhit AN, Bhagra A, Stead LG. Abdominal trauma: never underestimate it. *Case Rep Emerg Med* 2011;2011:850625. doi: 10.1155/2011/850625.
3. Hou MM, Tsou YK. Gastrointestinal: acute colonic intramural hematoma after blunt abdominal trauma. *J Gastroenterol Hepatol* 2009;24(3):494. doi: 10.1111/j.1440-1746.2009.05832.
4. Hazer B, Tanoglu A, Pesluk O, Inanli A. Post-traumatic intramural duodenal hematoma due to blunt abdominal trauma: case report. *Gulhane Med J* 2015;57(4):436-438. doi: 10.5455/gulhane.151422.
5. Edwards MK, Kuppler CS, Croft CA, Eason-Bates HM. Adhesive closed-loop small bowel obstruction. *Clin Pract Cases Emerg Med* 2018;2(1):31-34. doi: 10.5811/cpcem.2017.10.35927.
6. Sudakoff GS, Rosen MP, Rybicki FJ, et al. ACR Appropriateness Criteria: Blunt Abdominal Trauma. Available at <https://acsearch.acr.org/docs/69409/Narrative/>. American College of Radiology. Accessed July 26, 2018.
7. Roccarina D, Garcovich M, Ainora ME, et al. Diagnosis of bowel diseases: the role of imaging and ultrasonography. *World J Gastroenterol*. 2013;19(14):2144-2153. doi: 10.3748/wjg.v19.i14.2144. 7
8. Jones EL, Stovall RT, Jones TS, et al. Intra-abdominal injury following blunt trauma becomes clinically apparent within 9 hours. *J Trauma Acute Care Surg* 2014;76(4):1020-1023. doi: 10.1097/TA.000000000000131.