



Fever of Unknown Origin? Think Small! A Case of Anaplasmosis

Schyla Wante MS-IV, Paul Zgurzynski MD

University of Massachusetts Medical School; UMass Memorial Medical Center



INTRODUCTION

Anaplasma phagocytophilum was discovered to be the culprit bacterium causing human granulocytic anaplasmosis in 1994.^{1,5} Since its discovery, the incidence of anaplasmosis has been seen to be the highest in the northern Midwest and the Northeast US. In Massachusetts in 2017 there were over 9.4 cases of anaplasmosis per million people. Incidence has also been increasing over the past 20 years since its discovery, with 348 cases in 2000, 1761 cases in 2010, to 5762 cases in 2017.⁴ It is primarily spread through tick bites from the Ixodes scapularis tick, otherwise known as the deer or blacklegged tick (Figure 1).




Figure 1. Adult ticks range in size from 1-5mm, and are not commonly seen on exam in patients presenting with tick borne illnesses

CASE DESCRIPTION

History: A 60-year-old male presented to the ED for evaluation of right flank pain, fever, and vomiting. Patient had intermittent subjective fevers and chills increasing in frequency over the prior 3 days. In the ED he presented with sudden onset right flank pain, nausea, and vomiting that felt similar to prior kidney stones. He was returning from vacation in Maine, and lives in Massachusetts in a heavily wooded area. No abdominal pain, diarrhea, hematuria, rash, or headache. He had never seen a tick on him, but family members have had Lyme disease.

- **PMHx:** recurrent nephrolithiasis. Surgical history: lithotripsy.
- Otherwise denied daily medications, allergies, tobacco use, alcohol use, other drug use.

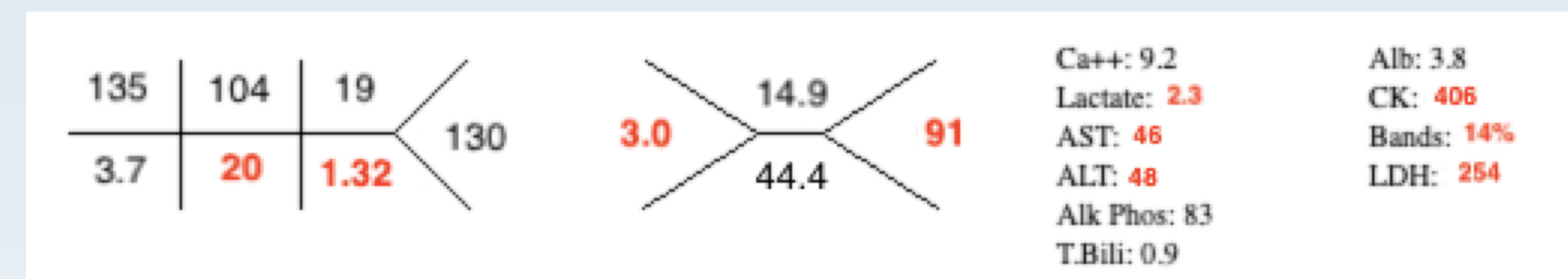Physical Exam:

VS: T- **102.3F**, HR- 98, RR-15, BP- 131/70, SpO2- 96% RA.
General: Uncomfortable appearing, **diaphoretic**.
Abd: Moderate **RUQ** tenderness to palpation.
Back: **Right CVA** tenderness
Skin: No rashes or ticks seen.

DIAGNOSIS & MANAGEMENT

Differential diagnoses initially included obstructing kidney stone, septic stone, and pyelonephritis. Septic work up completed, including blood cultures and empiric antibiotic treatment with Vancomycin and Piperacillin/Tazobactam. **Doxycycline** started and **tick panel** labs sent once initial labs resulted and social history confirmed likely exposure to ticks.

Initial labs:



Urinalysis: Blood: 2+, RBC: 3, Leuk esterase: negative, nitrite: negative

Blood Cultures and **tick panels** sent, and were pending at the time of admission.

CT Abd/Pelvis with contrast: no obstructing stones, no intraabdominal pathology

FOLLOW UP

Patient was started on vancomycin, piperacillin/tazobactam, and doxycycline for sepsis due to presumed tick borne illness and admitted to general medicine for further workup. Later labs resulted: **Anaplasma Phagocyto DNA PCR: Detected**

Patient continued to be intermittently febrile, LFTs rose to **AST: 80** and **ALT: 65**. Patient discharged on hospital day 3. He finished a course of **Doxycycline 100mg PO BID x 14 days**. On follow up 1 month post discharge lab values had normalized.

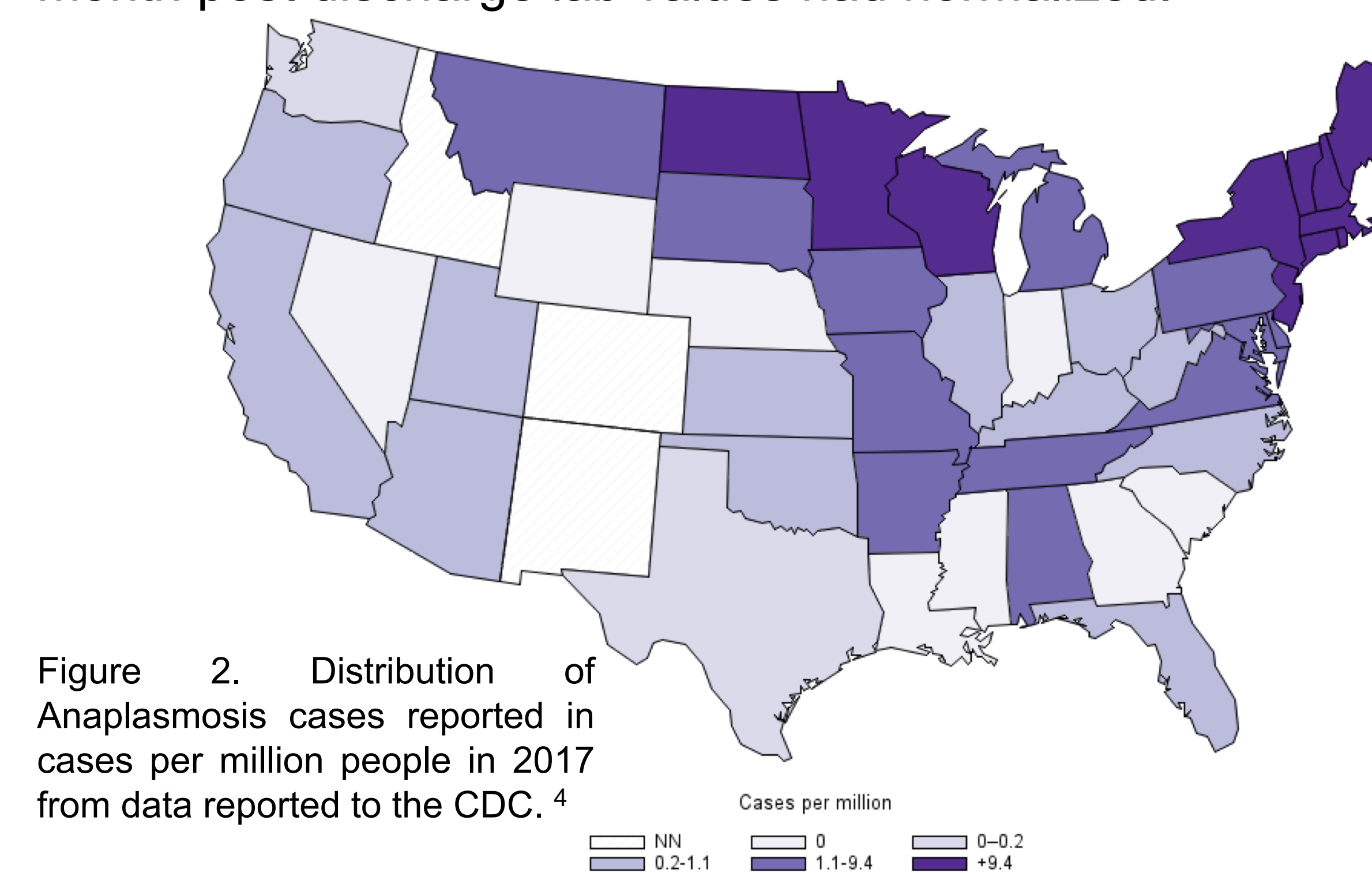


Figure 2. Distribution of Anaplasmosis cases reported in cases per million people in 2017 from data reported to the CDC.⁴

CASE DISCUSSION

- Early symptoms of anaplasmosis are vague and overlap with many different diagnoses. Symptoms appear **~5.5 days after a tick bite**.²
- Common symptoms include fever, chills, myalgias, malaise, headache. Less common symptoms include nausea, vomiting, cough, and arthralgias.²
- Clinical data including the patient's leukopenia, thrombocytopenia, and mildly elevated transaminases supported tick borne illnesses on our differential. Anaplasmosis is also commonly associated with a left shift, anemia, and elevated alkaline phosphatase.
- This case highlights the importance of the social history when time allows. Avoiding premature closure for diagnosis in this case was also key. It is necessary to keep tick borne illnesses in mind in endemic areas (Figure 2) in the spring and summer months.
 - Peak months for infection are June and July⁴
- Early treatment even prior to definitive diagnosis by PCR testing is imperative. Delays in treatment may result in increased rates of mechanical ventilation and longer hospital stays.⁶
- Rare complications of untreated anaplasmosis include renal failure, respiratory failure, peripheral neuropathy, DIC, rhabdomyolysis, and hemorrhage.⁶
- The recommended treatment of anaplasmosis is **doxycycline PO, 100mg BID for 10-14 days**.⁶

CONCLUSION

Patients with fever of unknown origin in the spring and summer months, with exposure to ticks must have tick borne illnesses on the differential diagnosis. Diagnosis of tick borne illnesses, including anaplasmosis, may be difficult due to vague symptoms and subacute presentations. Preemptive treatment with doxycycline should be started regardless of definitive diagnosis with laboratory testing if clinical suspicion is high due to the severity of complications of untreated tick borne illnesses and the ease of treatment.

REFERENCES

1. Bakken, Johan S., and Dumler JS. Human granulocytic anaplasmosis. *Infect Dis Clin North Am* 2015;341-355.
2. Centers for Disease Control and Prevention. Diagnosis and management of tickborne rickettsial diseases: Rocky Mountain spotted fever and other spotted fever group rickettsioses, ehrlichioses, and anaplasmosis—United States: a practical guide for health care and public health professionals. *MMWR* 2016;65 (No.RR-2).
3. Centers for Disease Control and Prevention (CDC). Summary of notifiable diseases—United States, 2010. *MMWR Morb Mortal Wkly Rep* 2012; 59:1.
4. The Centers for Disease Control and Prevention. Anaplasmosis statistics and epidemiology. <http://www.cdc.gov/anaplasmosis/stats/index.html>
5. Chen SM, Dumler JS, Bakken JS, Walker DH. Identification of a granulocytotropic Ehrlichia species as the etiologic agent of human disease. *J Clin Microbiol* 1994; 32:589.
6. Hamburg BJ, Storch GA, Micek ST, Kollef MH. The importance of early treatment with doxycycline in human ehrlichiosis. *Medicine (Baltimore)* 2008; 87:53.