



Teenage Chest Pain – Lesson Learned

Piotr Jurgielewicz

Pennsylvania State University College of Medicine



PennState
College of Medicine

Introduction

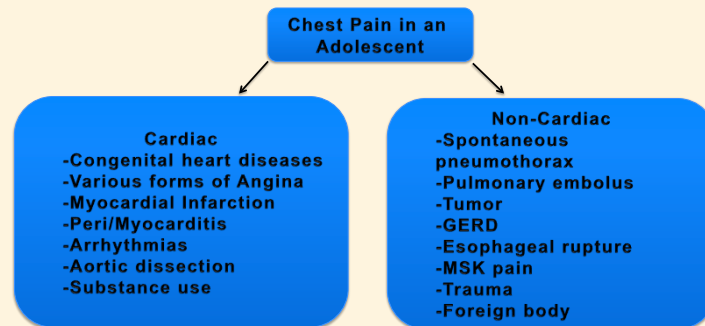
Acute myopericarditis refers to the inflammation of the pericardium and myocardium. Many times pericarditis and myocarditis present individual; however, it is not uncommon to see involvement of both structures due to their close anatomic proximity¹. The etiologies of myocarditis and acute pericarditis have much overlap, with most cases having an infectious origin. Other etiologies include: autoimmune, cardiac (post MI), metabolic, trauma, drugs and radiation². NSAIDs appear to be the mainstay therapy, with a good prognosis^{1,2}.

Pericarditis is an important differential in the emergency department for patients presenting with a chief complaint of chest pain. Recurrent idiopathic pericarditis occurs in as many as 30% of cases of acute pericarditis. Overall, such cases have a good long-term prognosis with little risk of major complications. In many cases, the definitive etiology cannot be identified. The mainstay medical therapy is aspirin or NSAID plus colchicine; second-line therapy consists of low to moderate doses of corticosteroids plus colchicine⁴. Typically, the diagnosis can be established with a history and physical exam, accompanied by testing such as ECG, troponins, Echo, chest x-ray².

Methods/Procedure

A 19-year-old male presented to the emergency department with chest pain, shortness of breath and nausea. He reported feeling ill 2 days prior to the onset of pain. History was negative for any cardiac condition. Family history was notable for a father that died of an MI at age 45. Vital signs were: T 100.7F, BP 116/87, HR 115. On physical exam, the patient was diaphoretic. Lung and cardiac exam were benign.

Differential Diagnosis



An ECG revealed diffuse ST elevations. Troponins were elevated at 573 ng/L. His ECG (see Figure 1) and clinical picture were consistent with pericarditis rather than a STEMI. The ED consulted internal medicine, infectious disease and cardiology for advice on how to proceed. A decision was made to hospitalize the patient for a work-up. The patient was placed on Naproxen, colchicine and prednisone. Viral panel for Coxsackie B, Influenza, and echoviruses was negative. Blood cultures for common bacterial infections were negative as well. An echocardiogram showed no effusion with no wall motion abnormalities. A myocardial/pericardial biopsy showed a small amount of pericardial effusion. Otherwise, the pericardium and myocardium appeared normal without evidence of myopericarditis.

Methods/Procedure.

Patient was given a diagnosis of myopericarditis and was discharged with colchicine, prednisone and Naproxen with outpatient cardiology follow up. The patient re-presented to the emergency department 9 days later with the same symptoms. EKG showed ST elevations across several leads and troponins were elevated at 456 ng/L. The patient was taken to the cath lab; coronary angiography showed no narrowing or signs of occlusion in any of the coronary arteries.

Other lab tests performed at re-presentation (all negative):

- Viral Panel
- Lyme disease titer
- Autoimmune disease work up
- Bacterial and fungal blood cultures
- PPD skin test
- Urine drug screen

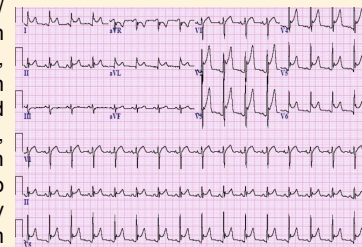


Figure 1. ECG on initial presentation

Clinical Discussion

Various specialists recommended different anti-inflammatory agents, leading to the patient being started and discharged on steroids and 2 anti-inflammatory agents; the combination of the two is known to cause kidney damage. A more thorough workup wasn't necessary since the presentation was not severe and a more ominous etiology was not suspected.

Conclusions

The case demonstrates how a multi-specialty intervention can lead to an excessive diagnostic work up in terms of costs, healthcare utilization and patient safety. Additionally, consultation from multiple services can lead to utilizing too many medications that can have potentially synergistic adverse effects.

References

- 1) Imazio M, Trinchero R. The spectrum of inflammatory myopericardial diseases. *Int J Cardiol.* 2010 Sep;144(1):134. Epub 2009 Jan 28.
- 2) Imazio M, Trinchero R. Myopericarditis: Etiology, management, and prognosis. *Int J Cardiol.* 2008 Jun;127(1):17-26. Epub 2008 Jan 24.
- 3) Imazio M, Battaia A, Gaido L, Gaita F. Recurrent pericarditis. *Rev Med Interne.* 2017 May; 38(5):307-311
- 4) Leonard S, Lilly. Treatment of Acute and Recurrent Idiopathic Pericarditis *Circulation.* 2013;127:1723-1726