

Hannah Gordon, MPH, MS-IV; Burr Fong, DO; Brad Koschel, DO, PGY-3; Michael Rosselli, MD; Michael Dalley, DO
Emergency Medicine Residency Program, Mount Sinai Medical Center, Miami Beach, FL

Introduction

Cryptococcal meningitis is most commonly found in HIV positive patients with a CD4 < 100. The infrequency in which it is encountered outside of Sub-Saharan Africa and its variable physical exam presentation makes it a diagnostic challenge in the United States.

Case Description

A 69 year old male with a past history of hypertension, bronchitis, diabetes mellitus type 2, and hypothyroidism presented to our ED with 1 week nausea, vomiting and headache. He was seen in an urgent care center five days prior, told he was influenza + and started on Tamiflu and clarithromycin. He came into another ED 4 days prior for the same issues and was sent home with Phenergan. Patient stated he was persistently vomiting 4-5 times daily at home for past 3 days, still with HA. He is now hypertensive (170/89) for 2 days and he cannot hold down his oral hypertension medications. Other systems reviewed and negative except a mild dry cough beginning 1 month ago.

-VS: 170/89 – HR 78 – RR 17 – 94% RA – 100.1 F – BMI 38

-Normal neurological exam with neck ROM intact, neg nuchal tenderness, neg Brudzinski's sign, chin to chest with no pain.

-CBC, BMP, lipase, LFTs, blood culture, UA and culture, LA, CXR ordered and he is started on NS, Toradol, and Reglan.

- CT brain negative. Patient declines lumbar puncture.

- On reassessment, nausea resolved, but HA persisted. Lactic acid is 2.1. Patient is admitted for possible meningitis and started on Vancomycin, Ceftriaxone.

- ID is consulted and diagnoses patient with HSV meningitis. Antibiotics are stopped. Patient refuses LP again.

- On day 5, patient becomes more confused, tells primary team that he wants to "jump out of the window." Speech is noted to be slurred, and he is disoriented to time. He states he is 12 years old. Mild right facial droop was seen. A stroke alert was called on the patient.

- Repeat CT brain showed findings concerning for PRES syndrome.

Case Description

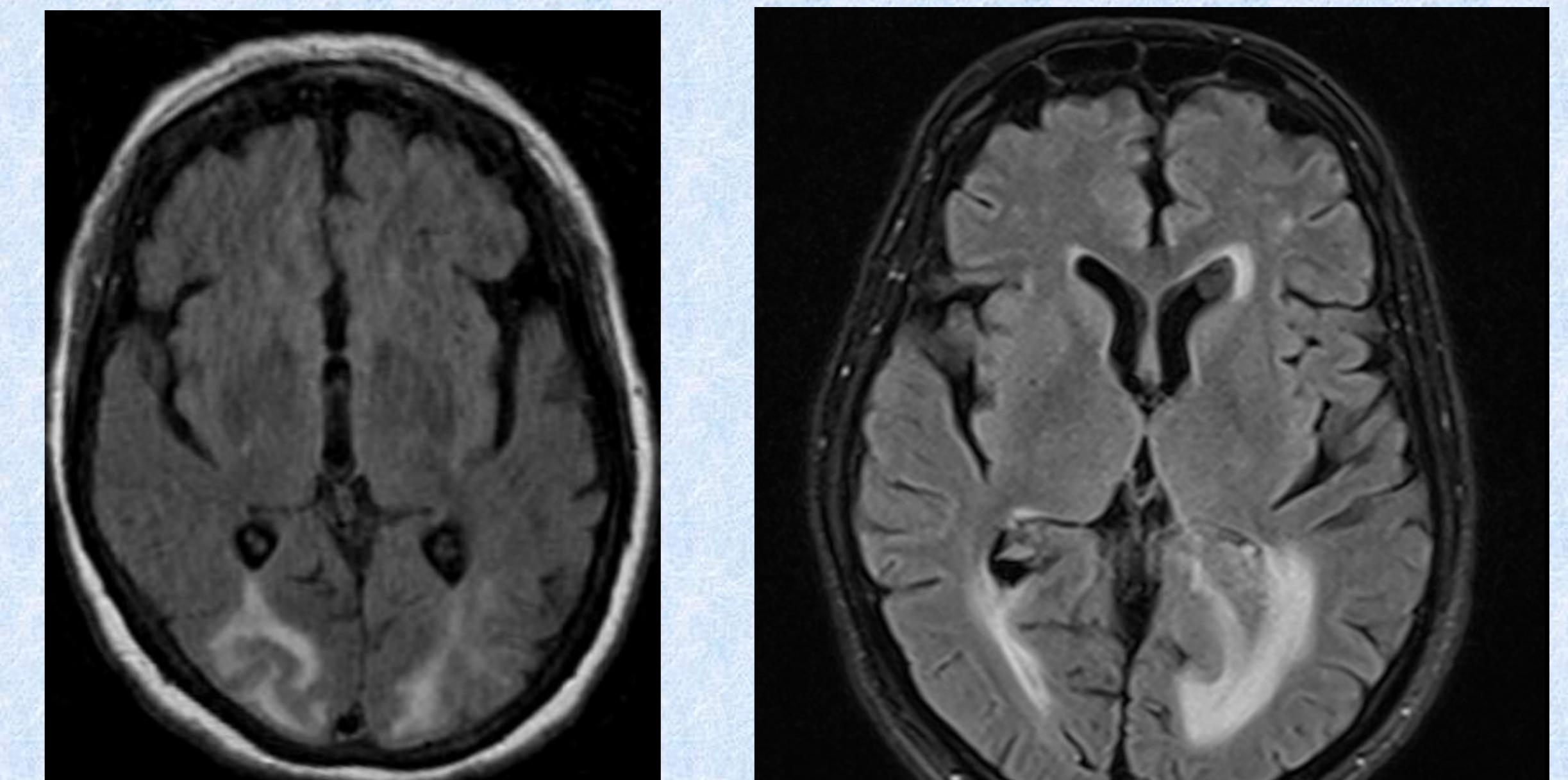
- Patient then developed fever of 38.5° C so repeat blood cultures were ordered. Patient is restarted on antibiotic therapy for possible bacterial meningitis and transferred to step down.
- Male partner continues to refuse LP. At this point, the primary team's main differential is aseptic meningitis vs. PRES syndrome. Patient refuses MRI.
- On hospital day 7, his sats drop, he is intubated and transferred to the ICU.
- Blood cultures come back positive for 1 out of 2 yeasts. He is started on diflucan, amphotericin and flucytosine. HIV/T cell subset ordered. Partner finally consents to LP. HIV comes back positive. CD4 count found to be 70. LP comes back positive for crypto antigen. Despite diagnosis and treatment, the patient's condition worsened on hospital day 9 and he goes into septic shock with adrenal insufficiency. Patient dies.

Discussion

Well-known for its presence in pigeon droppings, cryptococcus has an incidence of 1 million people a year with a reported 60% mortality. It begins indolently over weeks and generally presents similarly to the common cold. **Neck stiffness, photophobia, and vomiting are seen in only 20-30% of patients. Kernig's and Brudzinski's sign are only 2-5% sensitive.** Cryptococcal antigen does not correlate with severity of disease. Guidelines dictate using an LP to confirm diagnosis. If lesions noted on CT, differential includes toxoplasmosis, lymphoma, and TB. Positive crypto antigen is highly suggestive of disease and becomes positive before CSF culture becomes positive. Encapsulated, round yeasts are seen with india ink staining on pathology. A lumbar drain is needed for opening pressures >20 cch20. Treatment includes Amphotericin and Flucytosine for 2 weeks then Diflucan for 10 weeks. Repeat LP 2 weeks after initiating treatment.

Posterior reversible encephalopathy syndrome (PRES), is a syndrome characterized by headache, confusion, seizures and visual loss and is not traditionally included on the cryptococcal differential. It is thought to result from failure of blood pressure autoregulation and may occur due to a variety of causes, including malignant hypertension and eclampsia.

PRES vs Cryptococcus on CT



Case courtesy of Dr Paul Simkin, Radiopaedia.org, rID: 30476 and Dr Sathiyaseelan Maniharan, Radiopaedia.org, rID: 52316

Conclusion

Prompt diagnosis of Cryptococcal meningitis may be elusive without a known prior HIV diagnosis or underlying immunocompromise. Despite what is taught in medical school, several studies have shown Kernig's sign, Brudzinski's sign, and nuchal rigidity do not have diagnostic value in adults with meningitis. However, almost all meningitis patients present with at least 2 of the 4 symptoms of headache, fever, neck stiffness, and altered mental status. Therefore, do not always expect to see all of these (not so) "typical" meningeal signs and symptoms.

References

1. Desalermos A, et al. Update on epidemiology and management of Cryptococcal meningitis. Expert opinion pharmacotherapy 2012; 13:783.
2. Rex JH, Larsen RA, Dismukes WE, et al. Catastrophic visual loss due to Cryptococcus neoformans meningitis. Medicine (Baltimore) 1993; 72:207.
3. Sánchez-Portocarrero J, Pérez-Cecilia E. Intracerebral mass lesions in patients with human immunodeficiency virus infection and Cryptococcal meningitis. Diagn Microbiol Infect Dis 1997; 29:193.
4. Garlipp CR, Rossi CL, Bottini PV. Cerebrospinal fluid profiles in acquired immunodeficiency syndrome with and without neurocryptococcosis. Rev Inst Med Trop Sao Paulo 1997; 39:323.
5. Uchiyama and Tsukagoshi. The most sensitive sign of CSF pleocytosis. Headache 31: 167-171, 1991
6. Van de Beek et al. Steroids in adults with acute bacterial meningitis: a systemic review. Lancet Infect Dis 2004; 4: 139-143.
7. Thomas et al. The diagnostic accuracy of Kernig's sign, Brudzinski's sign and nuchal rigidity in adults with suspected meningitis. CID. 2002, 35: 46-52.
8. Proulx et al. Delays in administration of antibiotics are associated with mortality from adult acute bacterial meningitis. Q J Med. 2005, 98: 291-298.
9. Tyler et al. Herpes simplex virus infections of the central nervous system: encephalitis and meningitis, including Mollaret's. Herpes suppl. 2004,2: 57a-64a.